METRICA
METRology Institutional CAtalog

ISTITUTO NAZIONALE DI RICERCA METROLOGICA
Repository Istituzionale

Can Low-Intensity Pulsed Ultrasound Treat Discrete Pulmonary Lesions in Patients With COVID-19?

Original
Can Low-Intensity Pulsed Ultrasound Treat Discrete Pulmonary Lesions in Patients With COVID-19? / Prada, Francesco; Cogliati, Chiara; Alessandra Wu, Maddalena; Durando, Giovanni; Montano, Nicola; Gaspare Vetrano, Ignazio; Calliada, Fabrizio; Bastianello, Stefano; Pichiecchio, Anna; Padilla, Frederic. - In: JOURNAL OF ULTRASOUND IN MEDICINE. - ISSN 0278-4297. - 40:7(2020), pp. 1445-1450. [10.1002/jum.15522]
Availability:
This version is available at: 11696/73470 since: 2022-08-24T08:14:22Z

Publisher:
WILEY

Published
DOI:10.1002/jum.15522

Terms of use:

This article is made available under terms and conditions as specified in the corresponding bibliographic description in the repository

Publisher copyright
WILEY
This article may be used for non-commercial purposes in accordance with Wiley Terms and Conditions for Use of Self-Archived Versions

(Article begins on next page)

12 October 2024

Can Low-Intensity Pulsed Ultrasound Treat Discrete Pulmonary Lesions in Patients With COVID-19?

Francesco Prada, MD
Ultrasound Neuroimaging and Therapy Laboratory, Fondazione Istituto di Ricovero e Cura a Carattere Scientifico Istituto Neurologico Carlo Besta, Milan, Italy
Department of Neurological Surgery, University of Virginia School of Medicine, Charlottesville, Virginia, USA
Focused Ultrasound Foundation, Charlottesville, Virginia, USA

Chiara Cogliati, MD and Maddalena Alessandra Wu, MD
Division of Internal Medicine, Azienda Socio Sanitaria Territoriale Fatebenefratelli–Sacco, Milan, Italy

Giovanni Durando, PhD
Ultrasound Laboratory, Istituto Nazionale di Ricerca Metrologica, Torino, Italy

Nicola Montano, MD
Department of Internal Medicine, Fondazione IRCCS Ca' Granda Ospedale Maggiore Policlinico, Milan, Italy
Department of Clinical Sciences and Community Health, University of Milan, Milan, Italy

Ignazio Gaspare Vetrano, MD
Ultrasound Neuroimaging and Therapy Laboratory, Fondazione Istituto di Ricovero e Cura a Carattere Scientifico Istituto Neurologico Carlo Besta, Milan, Italy

Fabrizio Calliada, MD
Department of Radiology, IRCCS Mondino Foundation, Pavia, Italy

Stefano Bastianello, MD and Anna Pichiecchio, MD
Department of Brain and Behavioral Neuroscience, University of Pavia, Pavia, Italy
Department of Neuroradiology, IRCCS Mondino Foundation, Pavia, Italy

Frederic Padilla, PhD
Department of Radiology, University of Virginia School of Medicine, Charlottesville, Virginia, USA
Focused Ultrasound Foundation, Charlottesville, Virginia, USA

Manuscript accepted for publication September 7, 2020.

All of the authors of this article have reported no disclosures.

Address correspondence to Frederic Padilla, PhD, Focused Ultrasound Foundation, 1230 Cedars Ct, Charlottesville, VA 22903, USA.

E-mail: fpadilla@fusfoundation.org

Abbreviations
COVID-19, coronavirus disease 2019; CT, computed tomography; LIPUS, low-intensity pulsed ultrasound; SARS-CoV-2, severe acute respiratory syndrome coronavirus 2; US, ultrasound

doi:10.1002/jum.15522

Since the outbreak of the new coronavirus (severe acute respiratory syndrome coronavirus 2 [SARS-CoV-2]) infection, lung ultrasound (US) has become a relevant tool in the point-of-care evaluation and monitoring of pulmonary alterations induced by SARS-CoV-2 infection at the bedside. We suggest in this commentary that US could also be effective to reduce lung inflammation and fibrosis in moderate-to-severe coronavirus disease 2019 (COVID-19)-related pneumonia.

The new coronavirus infection, which started in December 2019 in Wuhan, China,[1] is highly transmissible and primarily spreads through the respiratory tract by droplets, respiratory secretions, and direct contact.[2] Coronavirus disease 2019 may cause constitutional symptoms, among which are respiratory and

gastrointestinal symptoms, the most common being fever and cough with a median incubation period of 4 days.[3] The clinical spectrum is quite wide, ranging from mild flulike symptoms to rapidly evolving acute respiratory distress syndrome, respiratory failure, multiple-organ failure, and death.[4] Severe acute respiratory syndrome coronavirus 2 infection can be roughly divided into 3 stages: stage 1, an asymptomatic incubation period with or without detectable virus; stage 2, a nonsevere symptomatic period with the presence of the virus; and stage 3, a severe respiratory symptomatic stage with a high viral load.[1,4]

Lung inflammation is the main cause of life-threatening respiratory disorders in the severe stage: once severe lung damage occurs, efforts should be made to suppress inflammation and to manage the symptoms.[5] On chest computed tomography (CT), a bilateral distribution of ground glass opacities with or without consolidations in the posterior and peripheral lungs is the cardinal hallmark of patients with COVID-19.[6,7] Patchy, segmental, or multifocal consolidations, localized especially in subpleural areas or along bronchovascular bundles, are usually identified in patients with COVID-19.[8] Recent autopsies have confirmed that the lungs are filled with clear liquid jelly, much resembling the lungs of wet drowning.[9]

<H1>Low-Intensity Pulsed Ultrasound for Treatment of Patients With COVID-19</H1>.

The role of US has so far been restricted to lung imaging, and we are advocating for a dual role with therapeutic purposes. Point-of-care lung US has allowed the evaluation and monitoring of pulmonary alterations induced by SARS-CoV-2 infection at the bedside. Point-of-care US is a repeatable technique, which does not expose the patients to radiation. Point-of-care US imaging is easily implementable, rapid, and inexpensive compared to lung CT or chest radiography[10] and has emerged in recent years as an indispensable tool to facilitate diagnosis and rapid therapeutic management[11] for critically ill patients with acute respiratory failure.[12–14] Since the establishment of the so-called BLUE (bedside lung ultrasound in emergency) and FALLS (fluid administration limited by lung sonography) protocol decision trees to diagnose different lung diseases,[12] several studies have shown the accuracy of lung US in detecting lung diseases, including acute respiratory distress syndrome, and its noninferiority to chest radiography and clinical examination.[13] Lung US has high sensitivity for detecting pleural thickening, subpleural consolidation, and ground glass opacification equivalent to CT.[15] In patients with COVID-19,[16] the most frequent findings at lung US include an irregular, thickened, and disrupted pleural line; an interstitial pattern (namely represented by the presence of B-lines), which can be focal of diffuse, often bilateral, and can vary in quantity, becoming confluent until the so-called white lung, suggestive of interstitial-alveolar damage; and in later stages and in the most severe forms, pathologic appearances (irregular pleural line, interstitial pattern, small or bigger consolidations), which are usually interrupted by areas with a normal artifactual pattern (Figure 1).

However, US can also be used to induce a variety of biophysical effects with therapeutic intent, such as local thermal ablation of tissues by high-intensity focused US, with intensities in the hundreds to thousands of watts per square centimeter, used for the treatment of prostate cancer[17] and neurologic disorders such as an essential tremor.[18] Between these diagnostic and therapeutic regimens lies the so called low-intensity pulsed ultrasound (LIPUS) technique, in which a low US intensity is applied, with intensity typically less than 100 mW/cm^2 (ie, at the upper limit of diagnostic intensities) and up to 1 W/cm^2. Low-intensity pulsed US techniques aim at modulating the physical environment of the cells, in particular by mechanical stimulation and possibly by very mild local heating, which can induce vasodilatation and increased blood flow. Low-intensity pulsed US is delivered in a pulsed manner with long duty cycles and exposure times[19,20] and has been used to stimulate bone fracture healing[21] and wound healing and to treat soft tissue and musculoskeletal injuries.[22] The most common LIPUS parameters used, especially for bone healing, are LIPUS at a frequency of 1.5 MHz, pulsed with a pulse repetition frequency of 1 kHz, a duty cycle of 20%, and an intensity of 30 mW/cm^2, with daily sessions of 20 minutes. The literature on the bioeffects of LIPUS suggests that this technique may be relevant in the context of COVID-19.

In several preclinical studies, LIPUS was shown to be beneficial in mitigating inflammation and facilitating tissue repairs,[23] with anti-inflammatory effects of LIPUS that could be mediated by several mechanisms, including upregulation of anti-inflammatory

Figure 1. Lung US imaging in the context of COVID-19. The images show the distinctive features observed on lung US imaging and illustrate the acoustic path that makes these lesions amenable for LIPUS treatment. **A**, Interstitial pattern: multiple B-lines (vertical artifacts starting from the pleural line). **B**, Subpleural consolidation: a hypoechoic area with irregular margins and hyperechoic air spots is detectable.

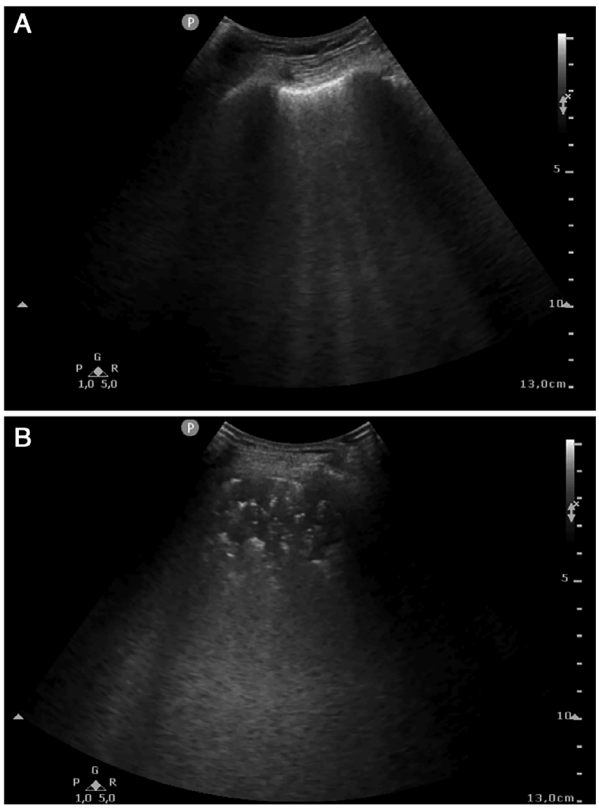

gene expression, upregulation of regulators of immunosuppressor cells, including myeloid-derived suppressor cells and regulatory T cells, and possibly through exosome-carrying anti-inflammatory cytokines and anti-inflammatory micro-RNAs.[24] The production of exosomes was also reported to possibly mitigate tumor necrosis factor α–induced endothelial inflammation by inhibiting the nuclear factor κB signaling pathway in human umbilical vein endothelial cells.[25] The potential of LIPUS to modulate the phenotype of inflammatory cells, reducing the number of neutrophils and inflammatory macrophages, was also observed in a preclinical model of spinal fusion[26] and muscle injury.[19] Reduced levels of inflammatory cyclooxygenase 2 after LIPUS were observed in animal models of rheumatoid arthritis[27] and tendon, skeletal muscle, ligament, and tendon-bone junction injuries,[22] although increased production of cyclooxygenase 2 was reported in LIPUS-treated fractures.[28]

Low-intensity pulsed US stimulation of angiogenesis was reported in the context of both bone and soft tissue repairs, through increased production of interleukin 8 and vascular endothelial growth factor by human mandibular osteoblasts, human peripheral blood monocytes, and human osteoblasts. Upregulation of vascular endothelial growth factor, endothelial nitric oxide synthase, and basic fibroblast growth factor was observed in a porcine model of chronic myocardial ischemia and was accompanied by an increase in capillary density in the ischemic region.[20]

Several preclinical studies reported that low-intensity US can inhibit edema formation in different tissue types, such as synovial inflammation in the rat knee[29] and in different mouse models of brain injuries.[30–32] The exact mechanisms of action remain to be elucidated, but the protective effect may be attributed to the maintenance of tight-junction proteins in the case of brain edema and to a reduction in the inflammatory cell infiltrate in the synovium.

Coronavirus disease 2019–driven endothelial damages have been documented.[33,34] Increased vascular permeability has been reported in some patients and seems to be strongly related to increased thrombosis. Published data suggest that LIPUS could play a mitigating role in this phenomenon. Basic research at the cellular and molecular levels suggests that LIPUS could attenuate endothelial inflammation.[25] In vitro, the inhibition of gap junctions abolished US-enhanced phosphorylation, suggesting that gap junctions are essential for the LIPUS effect, at least on osteogenic differentiation of mesenchymal stem cells. Low-intensity pulsed US exposure is able to improve cell-to-cell communication via gap junctions, mainly through modulation of extracellular signal–regulated kinase 1/2 and p38 intracellular signaling pathways.[21] Finally, low-intensity US has also been reported to induce changes in cell membrane permeability.[35]

In the context of a viral infection, a recent study reported that low-intensity US can attenuate the aggressive inflammatory response in a model of acute viral myocarditis in mice, with underlying mechanisms that may rely on activation of caveolin 1 and

suppression of mitogen-activated protein kinase signaling.[36] Whether these effects could be sufficient to reduce edema and endothelial damage and restore a functional endothelium, thus reducing thrombosis or ischemia, will have to be investigated.

On the safety side, as lungs naturally contain gas bodies, they are intrinsically more sensitive to the bioeffects of US exposure. Lung damage, hemorrhage that may result from the thermal, mechanical, or cavitational effects of US, has been reported in the past but with acoustic pressure levels of at least 1 MPa, well above LIPUS parameters proposed here, and these effects are dependent on the frequency, pulse duration, pulse repetition frequency, and exposure duration. To our knowledge, no adverse events have been reported with a LIPUS treatment regimen at low power in soft tissues.

The current LIPUS systems usually use planar transducers to sonicate a volume in front of the active surface of the sensor. It also would be theoretically possible to generate similar levels of pressure/power with diagnostic imaging systems, if the excitation parameters can be modified to send pulsed US (as imaging is performed by sending single pulses, whereas LIPUS uses pulsed continuous waves) in a planar mode (plane wave emission). That will have to be discussed with manufacturers. If possible, it could allow for an easy translation of this therapeutic modality in the clinical setting.

The proposed approach is limited to peripheral lesions adherent to the pleura, which could be treated through the corresponding transcostal acoustic window. Lesion accessibility, however, should be assessed at the time of imaging, and patients suitable for treatment would be patients with COVID-19 with moderate to severe inflammatory lung lesions adjacent to the chest wall as seen on chest CT scans and visible with transcostal US imaging.

A potential pitfall may come from technical limitations of the treatment area. Current LIPUS systems typically use planar transducers of a few centimeters in diameter, and treatment of lesions larger than the footprint of the transducer may lead to a suboptimal response. Selection of smaller lesions will allow this limitation to be bypassed at first, while technological solutions are implemented to allow treatment of larger areas if necessary. Finally, the treatment parameters proposed here are based on an analysis of published data, which report anti-inflammatory effects of LIPUS in the treatment of bone and soft tissues injuries. The basic dosimetric parameters of LIPUS and its mechanisms of action, however, have not been clearly identified yet,[21] and LIPUS parameters may have to be modified to induce an optimal response in patients with COVID-19.

Conclusions

Although LIPUS has not been studied specifically in the context of an inflammatory response yet, literature data suggest that LIPUS could be effective to reduce inflammation and improve blood circulation. Coronavirus disease–related pulmonary lesions, consisting of edematous tissue and fluid-filled cavities, usually in the peripheral lung areas, are visible with US imaging and are potentially amenable to treatment with therapeutic US. Coronavirus disease–related pleural/pulmonary consolidations can be treated with LIPUS with US imaging guidance or fusion imaging with CT scans.

The pathogenesis of COVID-19 deterioration is unknown. Moreover, the SARS-CoV-2 pandemic is an ongoing and unresolved medical emergency. It is important to provide relief to national health care systems by identifying potential strategies to reduce the rate of clinical deterioration. Ultrasound could have a direct clinical benefit for efficiently-treated patients and an indirect benefit for other patients because of the current shortage of intensive care unit equipment and personnel. The use of LIPUS, if proven effective, could be particularly important because of the current poor availability of potentially effective drugs to mechanically to reduce lung inflammation and fibrosis in moderate-to-severe COVID-19–related pneumonia. Further studies are now required to provide new insights into the applicability of LIPUS in everyday clinical practice (as an extended application of diagnostic tools) and also in other similar clinical settings, such as acute respiratory distress syndrome due to other etiologies.

References

1. Zhu N, Zhang D, Wang W, et al. A novel coronavirus from patients with pneumonia in China, 2019. *N Engl J Med* 2020; 382: 727–733.
2. Li Q, Guan X, Wu P, et al. Early transmission dynamics in Wuhan, China, of novel coronavirus-infected pneumonia. *N Engl J Med* 2020; 382:1199–1207.
3. Guan WJ, Ni Z, Hu Y, et al. Clinical characteristics of coronavirus disease 2019 in China. *N Engl J Med* 2020; 382:1708–1720.
4. Huang C, Wang Y, Li X, et al. Clinical features of patients infected with 2019 novel coronavirus in Wuhan, China. *Lancet* 2020; 395: 497–506.
5. Shi Y, Wang Y, Shao C, et al. COVID-19 infection: the perspectives on immune responses. *Cell Death Differ* 2020; 27:1451–1454.
6. Wang D, Hu B, Hu C, et al. Clinical characteristics of 138 hospitalized patients with 2019 novel coronavirus-infected pneumonia in Wuhan, China. *JAMA* 2020; 323:1061–1069.
7. Chung M, Bernheim A, Mei X, et al. CT imaging features of 2019 novel coronavirus (2019-nCoV). *Radiology* 2020; 295:202–207.
8. Bernheim A, Mei X, Huang M, et al. Chest CT findings in coronavirus disease-19 (COVID-19): relationship to duration of infection. *Radiology* 2020; 295:200463.
9. Xu Z, Shi L, Wang Y, et al. Pathological findings of COVID-19 associated with acute respiratory distress syndrome. *Lancet Respir Med* 2020; 8:420–422.
10. Buonsenso D, Pata D, Chiaretti A. COVID-19 outbreak: less stethoscope, more ultrasound. *Lancet Respir Med* 2020; 8:e27.
11. Islam M, Levitus M, Eisen L, Shhiloh A, Fein D. Lung ultrasound for the diagnosis and management of acute respiratory failure. *Lung* 2020; 198:1–11.
12. Lichtenstein DA. BLUE-protocol and FALLS-protocol: two applications of lung ultrasound in the critically ill. *Chest* 2015; 147: 1659–1670.
13. Volpicelli G, Elbarbary M, Blaivas M, et al. International evidence-based recommendations for point-of-care lung ultrasound. *Intensive Care Med* 2012; 38:577–591.
14. Nazerian P, Volpicelli G, Vanni S, et al. Accuracy of lung ultrasound for the diagnosis of consolidations when compared to chest computed tomography. *Am J Emerg Med* 2015; 33:620–625.
15. Cheung JCH, Lam KN. POCUS in COVID-19: pearls and pitfalls. *Lancet Respir Med* 2020; 8:e34.
16. Peng QY, Wang XT, Zhang LN. Chinese Critical Care Ultrasound Study group. Findings of lung ultrasonography of novel corona virus pneumonia during the 2019–2020 epidemic. *Intensive Care Med* 2020; 46:849–850.
17. Nahar B, Bhat A, Reis IM, et al. Prospective evaluation of focal high-intensity focused ultrasound (HIFU) for patients with localized prostate cancer. *J Urol* 2020; 204:483–489.
18. Walters H, Shah BB. Focused ultrasound and other lesioning therapies in movement disorders. *Curr Neurol Neurosci Rep* 2019; 19:66.
19. da Silva Junior EM, Mesquita-Ferrari RA, Cristiane Miranda França C, Andreo L, Kalil Bussadori S, Santos Fernandes KP. Modulating effect of low intensity pulsed ultrasound on the phenotype of inflammatory cells. *Biomed Pharmacother* 2017; 96: 1147–1153.
20. Hanawa K, Ito K, Aizawa K, et al. Low-intensity pulsed ultrasound induces angiogenesis and ameliorates left ventricular dysfunction in a porcine model of chronic myocardial ischemia. *PLoS One* 2014; 9:e104863.
21. Padilla F, Puts R, Vico L, Raum K. Stimulation of bone repair with ultrasound: a review of the possible mechanic effects. *Ultrasonics* 2014; 54:1125–1145.
22. Best TM, Wilk KE, Moorman CT, Draper DO. Low intensity ultrasound for promoting soft tissue healing: a systematic review of the literature and medical technology. *Intern Med Rev (Wash DC)* 2016; 2:271.
23. Jiang X, Savchenko O, Li Y, et al. A review of low-intensity pulsed ultrasound for therapeutic applications. *IEEE Trans Biomed Eng* 2019; 66:2704–2718.
24. Yang Q, Nanayakkara G, Drummer C, et al. Low-intensity ultrasound-induced anti-inflammatory effects are mediated by several new mechanisms including gene induction, immunosuppressor cell promotion, and enhancement of exosome biogenesis and docking. *Front Physiol* 2017; 8:818.
25. Li X, Li X, Lin J, Sun X, Ding Q. Exosomes derived from low-intensity pulsed ultrasound–treated dendritic cells suppress tumor necrosis factor–induced endothelial inflammation. *J Ultrasound Med* 2019; 38:2081–2091.
26. Zhang ZC, Yang YL, Li B, et al. Low-intensity pulsed ultrasound promotes spinal fusion by regulating macrophage polarization. *Biomed Pharmacother* 2019; 120:109499.
27. Nakamura T, Fujihara S, Yamamoto-Nagata K, Katsura T, Inubushi T, Tanaka E. Low-intensity pulsed ultrasound reduces the inflammatory activity of synovitis. *Ann Biomed Eng* 2011; 39: 2964–2971.
28. Harrison A, Lin S, Pounder N, Mikuni-Takagaki Y. Mode and mechanism of low intensity pulsed ultrasound (LIPUS) in fracture repair. *Ultrasonics* 2016; 70:45–52.
29. Chungy JI, Baruay S, Choiz BH, Minxk BH, Han HC, Baiky EJ. Anti-inflammatory effect of low intensity ultrasound (LIUS) on complete Freund's adjuvant–induced arthritis synovium. *Osteoarthritis Cartilage* 2012; 20:314–322.
30. Su WS, Wu CH, Chen SF, Yang FY. Low-intensity pulsed ultrasound improves behavioral and histological outcomes after experimental traumatic brain injury. *Sci Rep* 2017; 7: 15524.

31. Yoon SH, Kwon SK, Park SR, Min BH. Effect of ultrasound treatment on brain edema in a traumatic brain injury model with the weight drop method. *Pediatr Neurosurg* 2012; 48:102–108.
32. Karmacharya MB, Kim KH, Kim SY, et al. Low intensity ultrasound inhibits brain oedema formation in rats: potential action on AQP4 membrane localization. *Neuropathol Appl Neurobiol* 2015; 41:e80–e94.
33. Wu MA, Fossali T, Pandolfi L, et al. COVID-19: the key role of pulmonary capillary leakage—an observational cohort study [published online ahead of print May 21, 2020]. *medRxiv*. https://doi.org/10.1101/2020.05.17.20104877.
34. Marchetti M. COVID-19–driven endothelial damage: complement, HIF-1, and ABL2 are potential pathways of damage and targets for cure. *Ann Hematol* 2020; 99:1701–1707.
35. Domenici F, Brasili F, Cerroni B, et al. Differential effects on membrane permeability and viability of human keratinocyte cells undergoing very low intensity megasonic fields. *Sci Rep* 2017; 7:16536.
36. Zheng C, Wu SM, Lian H, et al. Low-intensity pulsed ultrasound attenuates cardiac inflammation of CVB3-induced viral myocarditis via regulation of caveolin-1 and MAPK pathways. *J Cell Mol Med* 2018; 23:1963–1975.